

SSU rRNA target amplification of intestinal microsporidia: A sensitive diagnostic tool for accurate estimate of its prevalence

Stuti Kaushik¹, Rumpa Saha¹, Shukla Das¹, V G Ramachandran¹, Ashish Goel²

¹Department of Microbiology and ²Department of Medicine,
University College of Medical Sciences & Guru Teg Bahadur Hospital, Delhi 110095

ABSTRACT

The diagnosis of intestinal microsporidiosis has traditionally relied on light microscopy. Western literature shows PCR to be more sensitive and specific. The present study was conducted to assess the prevalence of enteric microsporidiosis in HIV seropositive patients using PCR. Five percent stool samples were found to be positive for microsporidia by pan microsporidia primers and found to be *Enterocytozoon bieneusi* on amplification using species specific primers. Microsporidia is grossly under-reported in our country and there is a dire need to institute measures to detect this organism particularly in HIV infected individuals to abate morbidity and mortality due to this organism.

Keywords: Diarrhea, *Encephalitozoon*, *Enterocytozoon bieneusi*, HIV, microsporidia

INTRODUCTION

Microsporidia are obligate, intracellular, spore forming protozoan parasites which infect human beings. Humans are vulnerable to infection with thirteen different species belonging to seven genera including *Encephalitozoon* and *Enterocytozoon*. The first case of human microsporidiosis was documented in 1959 in Japan and subsequently after the dawn of HIV-AIDS era in 1980s, these organisms have emerged as important etiological agents of opportunistic infections in hosts who are immunocompromised.^[1]

The spectrum of disease in infected individuals includes chronic diarrhea and a wasting syndrome as the most common manifestation, and even as hepatitis, peritonitis, keratoconjunctivitis, sinusitis, bronchitis, pneumonia, cystitis, nephritis, myositis, encephalitis and other cerebral infections also occur. This protozoan

has emerged as an important enteric pathogen in patients with AIDS, with *Enterocytozoon bieneusi* and *Encephalitozoon intestinalis* being responsible for most cases. Enteric infections in AIDS patients due to *Encephalitozoon intestinalis* are likely to become disseminated.^[2] *Enterocytozoon bieneusi* is more commonly associated with chronic diarrhea in patients with AIDS in certain studies of the western world.^[3] It is imperative to identify the causative organism at the species level since *Enterocytozoon bieneusi* is known to be inherently resistant to albendazole, which is conventionally used in the treatment of intestinal microsporidiosis.

In the recent past, molecular techniques such as PCR that focus on small subunit (SSU) rRNA genes of microsporidia have been explored for detection as well as speciation of this organism. This has been possible due to limited homology of the SSU rRNA genes of microsporidia with other eukaryotic organisms and allows utility of these genes as probes in hybridization and PCR assays.^[4]

In the developing world, microsporidia is a neglected etiological agent of diarrhea in patients, especially in the HIV infected. Studies in the developing world including India on the HIV-microsporidia nexus and its amelioration arising out of pharmacological interventions are scarce. The paucity of proper

Corresponding author: Prof. Rumpa Saha
E-mail: rumpachatterjee@yahoo.co.in

Received: 12-07-2016

Accepted: 08-09-2016

How to cite this article: Kaushik S, Saha R, Das S, Ramachandran VG, Goel A. SSU rRNA target amplification of intestinal microsporidia: A sensitive diagnostic tool for accurate estimate of its prevalence. J Gastrointest Infect, 2016; 6:50-53

diagnostic facilities has led to gross under-reporting of this important parasite. Only a handful of studies have been conducted in India to ascertain the predominant species of microsporidia associated with enteric disease.^{15,61} To the best of our knowledge no studies on intestinal microsporidiosis have been undertaken in Delhi.

MATERIALS AND METHODS

The present cross-sectional observational study was conducted in our tertiary care hospital in east Delhi between November 2014 and April 2016 after obtaining Institutional ethics clearance and written consent from the patients.

A total of 60 HIV seropositive patients, all 12 years, who were ART naïve were included in the study and were further divided into two groups: (i) 30 HIV seropositive patients with diarrhea and (ii) 30 HIV seropositive patients without diarrhea. Subjects with history of intake of antiparasitic drugs, antibiotics or antimotility drugs in preceding two weeks were excluded.

Three consecutive fresh stool samples were collected and transported immediately to the Microbiology laboratory. Samples were subjected to routine processing and part of the sample was stored at -20°C for molecular work.

DNA from three stool samples of each subject was extracted using Qiagen 'QIAamp DNA Stool Mini Kit'(Germany) according to the manufacturer's protocol and quantified by nanodrop and stored at -20°C for further use. PCR was done using primers amplifying a conserved region of SSU rRNA gene of four common intestinal microsporidia: *Enterocytozoon bieneusi*, *Encephalitozoon intestinalis*, *E. cuculi* and *E. hellem*. Speciation for *Enterocytozoon bieneusi* and *Encephalitozoon intestinalis* were done using species specific primers. Sequences of primers are shown in Table 1.

Uniplex PCR amplification assay was performed with the DNA template for the four microsporidia mentioned above in thermo cycler (Eppendorf). The amplification protocol included an initial denaturation of DNA at 94°C for 5 mins followed by 30 cycles of denaturation at 94°C for 1 min, annealing at 56°C for 1 min, elongation at 72°C for 1 min and 5 mins of extension at 72°C after 30 cycles. Amplified products were electrophoretically analyzed on 1% agarose gel with ethidium bromide.

The samples showing a specific band of 1200 bp were subjected to PCR for speciation using species specific primers. Cycling conditions for *Enterocytozoon bieneusi* and *Encephalitozoon intestinalis* were initial denaturation of DNA at 94°C for 5 min followed by 35 cycles of denaturation at 94°C for 1 min, annealing at 50.2°C for 1 min (*Enterocytozoon bieneusi*), 58°C for 1 min (*Encephalitozoon intestinalis*), elongation at 72°C for 1 min and 5 min of extension at 72°C after 35 cycles.

RESULTS

Of a total of 60 HIV seropositive treatment naïve patients (30 with diarrhea and 30 without diarrhea), 5% (3/60) stool samples were found to be positive for microsporidia by pan microsporidia specific primers. Similar results were observed in all three consecutive stool samples. The three positives were found to be *Enterocytozoon bieneusi* on amplification using species specific primers (Fig 1). The patients infected with intestinal microsporidiosis were aged between 18 and 33 years with a male predominance.

Two of the three patients of intestinal microsporidiosis did not present with diarrhea and acute diarrhea was the presenting illness associated with nausea and vomiting in only one. The stool was semi-formed with frequency 10/day. This patient had an episode of diarrheal illness about 5 months back. The patient was in Stage 2 of clinical AIDS and the CD4 counts were below 100/mm³.

The other two patients did not have any enteric complaints. However, one of them affirmed to having a history of intermittent diarrhea three months before presentation. A history of significant weight loss was present in both of them. Clinical stage of AIDS at the time of presentation was Stage 3 and Stage 4 respectively. The CD4 counts were below 100/mm³ in both cases.

DISCUSSION

Aiming to detect the burden of intestinal microsporidiosis in HIV seropositive individuals in Delhi, the present study identified an overall prevalence of intestinal microsporidiosis in HIV seropositive individuals in Delhi to be 5% (3/60), which is comparable to studies from Gujarat and Chennai, where prevalence rates of 2% and 6.5% have been reported respectively.^{15,71} A higher prevalence of 15.9% in HIV seropositive individuals has been reported from Chandigarh.¹⁶¹

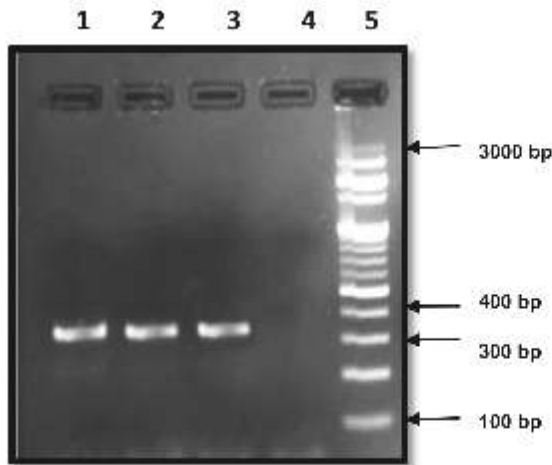


Fig. 1A

Lane 1: Positive control for *E. bieneusi*
 Lane 2 & 3: *E. bieneusi* positive samples (353 bp)
 Lane 4: Negative control
 Lane 5: 100 bp ladder

Fig. 1A: An agarose gel showing PCR products of human fecal samples with *Enterocytozoon bieneusi* specific primer

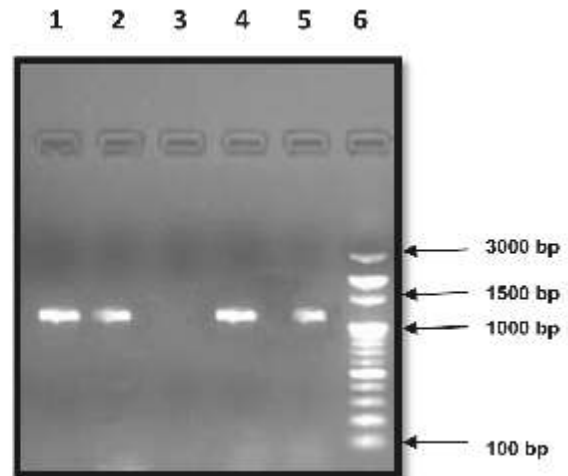


Fig. 1B

Lane 1: Positive control for pan Microsporidia (4 spp.)
 Lane 2, 4 & 5: Pan Microsporidia positive samples (1200 bp)
 Lane 3: Negative control
 Lane 6: 100 bp ladder

Fig. 1B: An agarose gel showing PCR products of human fecal samples with pan microsporidia primer

Table 1
DNA sequences of primers

Primer	Sequence	Amplicon (bp)	Species
Forward C1	5' CACCAGGTTGATTCTGCC3'	~ 1200	<i>Enterocytozoon bieneusi</i> , <i>Encephalitozoon intestinalis</i> , <i>E. hellem</i> , <i>E. cuniculi</i>
Reverse C2	5' GTGACGGGCGGTGTGTAC3'		
V1 Forward	5' CACCAGGTTGATTCTGCCTGA3'	353	<i>Enterocytozoon bieneusi</i>
EB450 Reverse	5' ACTCAGGTGTTATACTCACGTC3'		
V1 Forward	5' CACCAGGTTGATTCTGCCTGA3'	375	<i>Encephalitozoon intestinalis</i>
SI500 Reverse	5' CTCGCTCCTTACTACTCGAA3'		

Microsporidia detection in HIV seropositive individuals presenting with diarrhea in the present study was 3.33% (1/30) which is lower in comparison to studies from Mumbai (17.8%) and Pune (12.9%).^[8,9] A study from Chandigarh has documented even higher rates (30.4%).^[6] The prevalence of intestinal microsporidiosis in HIV seropositive patients without

diarrhea in the present study was 6.66% (2/30), akin to a report from Chandigarh (7.6%).^[6] The varying rates of prevalence in different regions of the country maybe due to different techniques used for detection. Whether or not, geographical and ethnic differences play any role needs to be further investigated.

In this study it was noted that diarrhea was present only in one of the three patients of enteric microsporidiosis indicating that diarrhea need not necessarily be present in such patients. The symptomatology was varied including nausea, vomiting, weight loss and generalized body ache. It was also observed that patients with enteric microsporidiosis can present at any clinical stage of AIDS. Anemia was noted in all 3 cases. The CD4 counts were below 100 mm³ in all patients with enteric microsporidiosis.

All (100%) patients of intestinal microsporidiosis in present study were due to *Enterocytozoon bieneusi*, perhaps the predominant species in Delhi, reiterating its preponderance in HIV seropositive individuals. *Encephalitozoon intestinalis* was not detected in any sample. Our findings are comparable to studies from Chennai (100%) and Lucknow (100%), but unlike that from Chandigarh where *Encephalitozoon intestinalis* was found to predominate.^[5,6,10] *Enterocytozoon bieneusi* also predominates in Vietnam.^[11] *Enterocytozoon bieneusi* exhibits intrinsic resistance to albendazole, which is conventionally used in the treatment of intestinal microsporidiosis and speciation if done well in time can prevent its dissemination in advanced stages of HIV disease.

The clinical diagnosis of intestinal microsporidiosis traditionally depends upon direct visualization of the parasite by light and electron microscopy, and sensitivity and specificity of these techniques are dependent on expertise of the microscopist. Transmission Electron Microscopy, the conventional gold standard for diagnosis of intestinal microsporidiosis has limitations of cost and expertise. The sampling error in electron microscopy may be overcome by immune electron microscopy but these were beyond the scope of the present study. PCR involves an initial DNA extraction step from stool samples where inhibitors present may decrease the effectiveness. However PCR still has the advantage of speciation when used with species specific primers, thus augmenting therapeutic and epidemiological importance.

Two asymptomatic patients who had no enteric complaints are of special interest. One of them had intermittent diarrhea months before the most recent therapeutic intervention raising the possibility of persistence of this parasite in the host and becoming active at an opportune time. The patients under discussion had significant weight loss along with low CD4 counts.

Microsporidia is grossly under-reported in our country and considering the varied manifestations, especially the potential to disseminate if undetected at early stages, may lead to avoidable complications. There is a dire need to institute measures to detect this organism particularly in HIV infected individuals to abate morbidity and mortality due to this organism.

ACKNOWLEDGEMENT

The authors would like to express their sincere gratitude towards Dr. Ujjala Ghoshal, Additional Professor, Department of Microbiology, SGPGI, Lucknow for providing the positive control sample of *Enterocytozoon bieneusi*.

SOURCE OF FUNDING: Institutional fund

CONFLICTS OF INTEREST: Nil

REFERENCES

1. Matsubayashi H, Koike T, Mikata T, Hagiwara S. A case of Encephalitozoon like body infection in man. Arch Pathol. 1959;67:181-7.
2. Orenstein JM, Dieterich DT, Kotler DP. Systemic dissemination by a newly recognized intestinal microsporidia species in AIDS. AIDS. 1992;6:1143-50.
3. Desportes I, Le Charpentier Y, Galian A, Bernard F, Cochand-Priollet B, Lavergne A *et al.* Occurrence of a new microsporidian: *Enterocytozoon bieneusi* n.g., n.sp., in the enterocytes of a human patient with AIDS. J Protozool. 1985;32:250-4.
4. Zhu X, Wittner M, Tanowitz HB, Kotler D, Cali A, Weiss LM. Small subunit rRNA sequence of *Enterocytozoon bieneusi* and its potential diagnostic role with use of the polymerase chain reaction. J Infect Dis. 1993;168:1570-5.
5. Satheesh KS, Ananthan S, Lakshmi P. Intestinal parasitic infections in HIV-infected patients with diarrhoea in Chennai. Indian J Med Microbiol. 2002;20:88-91.
6. Saigal K, Sharma A, Sehgal R, Sharma P, Malla N, Khurana S. Intestinal microsporidiosis in India: a two year study. Parasitol Int. 2013;62:53-6.
7. Gupta M, Sinha M, Raizada N. Opportunistic intestinal protozoan parasitic infection in HIV positive patients in Jamnagar, Gujrat. SAARC J Tuber Lung Dis HIV/AIDS. 2008;5:21-4.
8. Dalvi S, Mehta P, Koticha A, Gita N. Microsporidia as an emerging cause of parasitic diarrhoea in HIV seropositive individuals in Mumbai. Bombay Hosp J. 2006;48:592-7.
9. Kairon R. Study on opportunistic enteric parasites in HIV-seropositive adult patients hospitalized for diarrhoea. National AIDS Research Institute. Annual Report 2003. 2003-2004.
10. Ghoshal U, Khanduja S, Pant P, Prasad KN, Dhole TN, Sharma RK *et al.* Intestinal microsporidiosis in renal transplant recipients: Prevalence, predictors of occurrence and genetic characterization. Indian J Med Microbiol. 2015;33:357-63.
11. Espern A, Morio F, Miegerville M, Illa H, Abdoulaye M, Meyssonier V *et al.* Molecular study of microsporidiosis due to *Enterocytozoon bieneusi* and *Encephalitozoon intestinalis* among human immunodeficiency virus-infected patients from two geographical areas: Niamey, Niger, and Hanoi, Vietnam. J Clin Microbiol. 2007;45:2999-3002.